

ORIGINAL ARTICLE

Omohyoid Muscle: An Anatomical Study

Nandini Bhat¹, Arvind Kumar Pandey¹, Divya C¹, Sushma R. Kotian^{1*}, Sneha G Kalthur¹

¹Department of Anatomy, Kasturba Medical College Manipal, Manipal Academy of Higher Education, Manipal-576104 (Karnataka) India

Abstract:

Background: Variants of the omohyoid muscle are essential, because of their close relationship with the great vessels and brachial plexus. Due to direct attachment of the tendon to the wall of the internal jugular vein, muscle contraction has a direct influence on it. **Aim and Objectives:** The study was designed to understand the morphology and morphometry of the superior and inferior bellies the omohyoid along with its intermediate tendon. **Material and Methods:** The head and neck regions of 40 human cadavers (25 males and 15 females) were studied. The length and maximum width of the superior and inferior bellies of the omohyoid along with the intermediate tendon were measured. Also, an attempt was made to correlate the measurements of the muscle with the bony landmarks. **Results:** The superior belly of the omohyoid was absent in one of the specimens. In the remaining 39 specimens, there was no significant difference between the dimensions of superior and inferior bellies of the omohyoid in the right and left sides. But the length ($p=0.02$) and width ($p=0.03$) of the intermediate tendon showed a statistically significant difference between the right and left. Further the length of the neck when correlated with the dimensions of the omohyoid showed a positive linear relationship. **Conclusion:** This study provides a normal database for morphological and morphometric details of omohyoid muscle. It is significant from the surgical point of view as it is in close relation to the great vessels of the neck and certain group of lymph nodes.

Keywords: Omohyoid, Morphology, Morphometry, Hyoid Bone, Neck

Introduction:

Omohyoid is an infrahyoid muscle forms an important landmark for dividing the neck into various triangles and for the identification of essential structures of the neck. It comprises of Superior (SOH) and Inferior (IOH) bellies connected by an intermediate tendon. IOH originates from the upper border of the scapula and the superior transverse scapular ligament and ends in the Intermediate Tendon (IT). IT lies superficial to the internal jugular vein at the level of the cricoid cartilage and is attached to the clavicle through a facial pulley. The SOH begins at the IT and is attached to the lower border of the body of the hyoid bone [1].

The literature review revealed that SOH exhibits multiple unusual variations and insertion. The fusion of the omohyoid with sternohyoid has also been reported [1]. The deep group of cervical lymph nodes is divided by the IT into upper and lower groups. The jugulo-omohyoid lymph node, i.e., the principal lymph node of the tongue is situated in close approximation with the IT along with the internal jugular vein. It was also stated that the omohyoid muscle is also related to the brachial plexus and great vessels of the neck. Therefore, the muscle is of clinical importance as a consistent landmark [2-4].

Detailed knowledge of the variations in the morphology and morphometry of the muscles is of great importance during surgical procedures. It

helps to prevent iatrogenic injuries and positively aids in accurate examinations of the neck [5].

Although the studies in the past have focused on the abnormal morphology of the omohyoid, the normal morphometric data is lacking in the literature. Hence in the present study, an attempt was made to measure the length and width of both the bellies of omohyoid along with its IT and correlate it with the neck of the length.

Material and Methods:

The head and neck regions of 40 human cadavers (25 males and 15 females) were considered for the present study. The cadavers with gross malformations in the head and neck region were excluded from the study. For the dissection of the neck, the incision was made in the midline of the neck from the symphysis menti to jugular notch. The skin was reflected inferolaterally, and fibers of platysma were reflected upwards. The fat and fascia from the superficial surface and margins of the sternocleidomastoid were removed. The sternal head of sternocleidomastoid was drawn aside to expose the structures underneath. The IT of omohyoid was identified. The sternocleidomastoid muscle was cut at its origin and reflected towards its insertion carefully separating it from the deep structures. The attachment of the SOM to the hyoid bone and the distal attachment of IOM to the superior border of scapula were traced.

Length of the SOM from the hyoid bone to its IT was measured. The length of IOM from the IT to its scapular attachment was also measured. The maximum width of both the bellies and also the maximum width of the tendon were measured.

To correlate the morphometric findings, few bony landmarks were also considered, i.e., Length of the neck (the distance between the upper border of the hyoid bone to the suprasternal notch), the

distance between the base of the mandible to the intermediate tendon.

Statistical analysis of the morphometric measurements was done using EZR software (Version 3.3.2). The data were represented as mean \pm SD. The paired t-test was applied to find differences between the right and left. Pearson's correlation coefficient was determined to find the correlation between length of the neck and the length of the omohyoid muscle. The same was plotted on scatter plot graph.

Results:

The omohyoid muscle was studied for its morphology and morphometry in 40 cadavers. The normal anatomy of the SOH and IOH bellies of the omohyoid along with its IT was found in 39 cadavers (Fig. 1). During the study, a variation in the SOH was identified in one of the specimens (Fig. 2). The SOH did not have a normal muscular origin from the hyoid bone. Instead, it had a thin slip of tendinous origin from the lesser cornua of the hyoid bone that subsequently progressed downwards and backward to continue as the IT (Fig. 2a). The IOH, on the contrary, had a typical morphology. The muscle fibers originated from the superior border of the scapula and formed the intermediate tendon as usual. The nerve supply to the variant slip of SOH was provided by the loop of ansacervicalis as observed in the specimen (Fig.2b).

The length and width of the SOH and IOH along with the IT was measured. The specimen with variation was excluded from the morphometric study.

The length of the neck measured about (14.20 ± 1.07) cm. The length and width of the SOH were (6.45 ± 1.29) cm and (1.00 ± 0.47) cm respectively. The IOH measured about (5.15 ± 0.58) cm and

(0.57 ± 0.18) cm in length and width respectively. The length and width of the IT were (2.30 ± 0.27) cm and (0.49 ± 0.14) cm respectively. The distance between the mandible and the intermediate tendon measured about (8.66 ± 0.85) cm.

Statistically, there was no significant difference between dimensions of SOH and IOH in the right and left sides. But the length ($p=0.02$) and width

($p=0.03$) of the intermediate tendon showed a statistically significant difference between the right and left.

Further the length of the neck when correlated with the dimensions of the omohyoid showed a positive linear relationship, i.e., $r = 0.81, 0.58$ and 0.72 for the length of the SOH, IT and IOH respectively (Fig. 3).

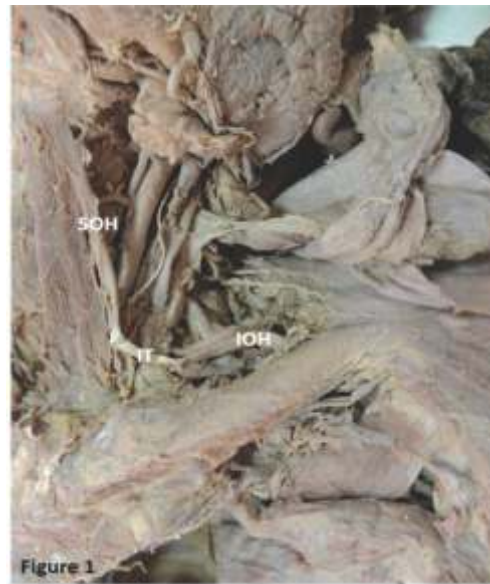

Fig. 1: Representative Image Showing the Normal Anatomy of the Omohyoid Muscle



Fig. 2: Showing the Absence of the Superior Belly of Omohyoid Muscle. It was Replaced by a Tendinous Slip (*) which Later Blended with the Sternohyoid (SH) Muscle and Attached to the Hyoid Bone (HY). IB- Inferior Belly of Omohyoid, CL-Clavicle, SCM- Sternocleidomastoid

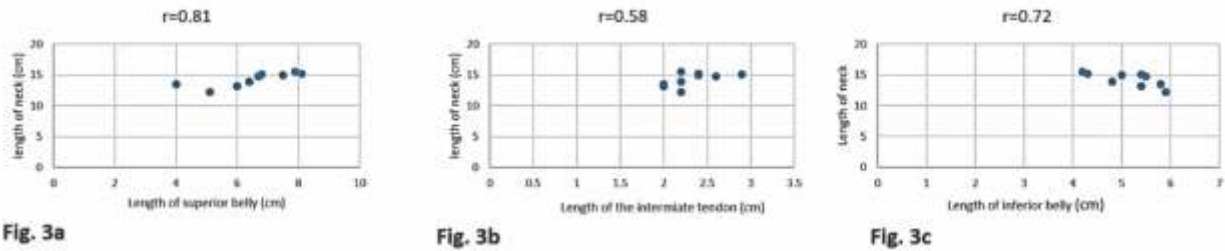


Fig. 3: Correlation between the Length of the Neck and Superior Belly of Omohyoid (Fig. 3a), Intermediate Tendon (Fig. 3b), Inferior belly of Omohyoid (Fig. 3c)

Discussion:

Important structures such as internal, external jugular vein, carotid arteries, and its branches are located in the vicinity of the omohyoid muscle. It is an essential landmark during surgical dissection of lymphnodes in stage III and IV metastasis of malignancy. There is a case report of cerebral insufficiency in the literature due to omohyoid muscle entrapment of internal jugular vein [6]. Hence any variation in the morphology of this muscle is imperative for diagnostic and treatment purposes.

There are many theories proposed by researchers for the development of infra hyoid muscles [4]. It was first proposed that the SOH belongs to the muscles of the hyoid bone, while the IOH may have a common origin with the subclavius muscle. This implied that both the bellies had a different source of origin [7]. According to Moore *et al.* the infrahyoid muscles are derived from the cervical myotomes unlike most of the muscles of the neck that arises from the branchial arches [8]. Buntine proposed that the omohyoid and sternohyoid muscles are the lateral and medial margins of the primitive sterno-cleido-omo-hyoid muscle [9].

Variations of the omohyoid muscle include: cleidofascialis, which originates from the middle one-third of the clavicle and inserts into the fascia colli (neck); cleidohyoideus, which originates

behind the origin of the cleidomastoid part of sternocleidomastoideus and inserts onto the body of the hyoid bone; and hyofascialis, which originates from the hyoid bone and inserts into the omosternoclavicular fascia [7].

The infrahyoid muscles originate from a muscle primordium present in the anterior cervical area [10]. The muscle primordium is initially divided into shallow and deep layers. Although the shallow layer becomes the splenius spread in the cervical region. In humans, the intermediate area degenerates and the splenius is separated into the internal and external muscles. The internal muscle becomes the sternohyoid muscle. The lower part of the external muscle grows in the external and inferior direction and becomes the omohyoid [11]. Therefore, the anomalies caused by the adhesion of the fetal omohyoid and the cleido-sternohyoideus are from the primitive morphology of the splenius. It has been suggested that because the human omohyoid is degenerating, the incidence of anomalies is high [9, 11, 12]. The variation of the missing SOH as described in the present study may be attributed to the same.

A study was done previously on 34 cadavers to identify the intermediate morphologies between the normal and anomalous origin of SOH. The intermediate morphologies were then classified

into four types based on the degree of development of the muscle fibers and the number and origin of the belly. The variation that we noticed in our study fit into the first type which is underdevelopment of the myofibres of superior belly [5].

Murthy *et al.* have reported two cases wherein the SOH was absent unilaterally. In its place, a fibrous band was seen from the IT to the hyoid bone [3]. These findings are similar to the variation that we identified in our study.

In a study conducted by Rai on 35 cadavers, she found four patterns of variability; the first pattern was the usual origin and insertion which was seen in 85% cases. The existence of the cleidohyoideus, double omohyoid, and also a short omohyoid was identified. The SOH receiving slips from sternum was also explained in their study [13]. In the present study, we found the normal pattern in 90% of cases.

According to Mizen and Mitchell's cadaveric and clinical study on 30 cadavers and 88 patients,

there was no significant correlation between age of the patient and the distance between the omohyoid and clavicle. Additionally, they also noted that there was no significant correlation between length of the neck and omohyoid to clavicle measurement [14].

In the present study, we have attempted to record the lengths and widths of the SOH, IOH and IT. Additionally, we also found a positive correlation between the length of the neck and the lengths of the SOH, IOH and IT.

Conclusion:

The previous studies have all reported variation in origin, insertion, and morphology of the muscle. However, in our study we have reported the morphometric measurements of the muscle that is lacking in the literature. Thorough knowledge of the morphometric details and the morphological variations are significant from the surgical point of view as it is in close relation to the great vessels of the neck. Also, this area is frequently accessed by the oncologists for excision of lymph nodes.

References

1. Standring S. Gray's anatomy: The anatomical basis of clinical practice, 39th Ed, Edinburgh: Churchill and Livingstone 2005: 538-39.
2. Dutta AK. Essentials of human anatomy: Head and Neck, 4th Ed, Current books international: Kolkata 2004: 191-93.
3. Murthy KS, Kauser ST, Appaji AC, Komala N. Variant Omohyoid Muscle: Report of Two Cases. *Int J Anat Res* 2015; 3(2):991-94.
4. Noussios G. Omohyoid Muscle's Interesting Anatomical Variations – Review of the Literature. *The Internet J Human Anat* 2015; 3(1): 1-7.
5. Sukekawa R, Itoh I. Anatomical study of the human omohyoid muscle: regarding intermediate morphologies between normal and anomalous morphologies of the superior belly. *Anat Sci Int* 2006; 81:107-14.
6. Gianesini S, Menegatti E, Mascoli F, Salvi F, Bastianello S, Zamboni P. The omohyoid muscle entrapment of the internal jugular vein. A still unclear pathogenetic mechanism. *Phlebology* 2014; 29(9):632-5.
7. Bergman RA, Afifi AK and Miyauchi R. Illustrated Encyclopedia of Human Anatomic Variation: Muscular System: Omohyoideus, Sternohyoideus, Thyrohyoideus, Sternothyroideus. 1996. <http://www.anatomyatlases.org/AnatomicVariants/MuscularSystem/MuscleGroupings/21Infrahyoid.shtml>
8. Moore KL. Clinically Oriented Anatomy, 3rd ed, Williams & Wilkins. A Waverly Company, Baltimore 1992: 797.
9. Buntine JA. The omohyoid muscle and fascia. *Aust NZ Surg* 1970; 40:86-8.

-
10. Lewis WH. The development of the muscular system. In: Manual of Human Embryology, 1st Ed (Keibel F, Mall FP, eds), Lippincott: Philadelphia 1910:454-522.
 11. Takano T, Takaya M, Iizuka K. A statistical study of abnormal muscle of infrahyoid. *Iwateidai Kaibou Gyouseki* 1955; 2:113-24.
 12. Sato Y, Oota Y, Yokota A, La anomalio de M. omohyoideus ce Japanoj. *Nichidai Igaku Z* 1969; 28:431-4.
 13. Rai R I, Ranade A, Nayak S, Vadgaonkar R, Mangala P, Krishnamurthy A. A study of anatomical variability of the omohyoid muscle and its clinical relevance. *Clinics (Sao Paulo)* 2008; 63(4):521-4.
 14. Mizen KD, Mitchell DA. Anatomical variability of omohyoid and its relevance in oropharyngeal cancer. *Br J Oral Maxillofac Surg* 2005; 43(4):285-8.
-

**Author for Correspondence: Dr. Sushma R Kotian, Assistant Professor, Department of Anatomy, Kasturba Medical College Manipal, Manipal Academy of Higher Education, Manipal- 576104, Karnataka, India
Email: sushma.rk@manipal.edu Cell: 09880895097*